ScienceDirect

JCA Advances

Volume 2, Issue 4, December 2025, 100166

Analgesic outcomes following ultrasound-guided intercostal cryoneurolysis in oncologic thoracic surgery – A case series

Andrzej P. Kwater MD [a], Keyuri Popat MD [a], Evan J. Wright MD [c], David C. Rice MD [b], Ravi Rajaram MD [b], Gabriel E. Mena MD [a]

Show more

Outline | Share Cite

https://doi.org/10.1016/j.jcadva.2025.100166

Get rights and content

Under a Creative Commons license

Open access

Abstract

Thoracic surgery remains a cornerstone in oncologic management of chest malignancies, yet despite advancements in surgical techniques and incorporation of enhanced recovery protocols, post-thoracotomy pain syndrome (PTPS) and prolonged post-surgical pain continue to be prevalent complications. Comprehensive multimodal management, including utilization of non-opioid analgesics and regional/neuraxial anesthesia, is essential for treatment of postoperative pain but even these strategies have limitations. Post-thoracotomy patients are at high risk of symptom progression to chronic pain, and often rely on prolonged opioid use to manage debilitating impacts on physical functioning and quality of life.

More recently, the use of percutaneous cryoneurolysis has expanded to acute pain management, with the goal of extending analgesic effect. We describe a series of four cases in which patients presented with unrelenting pain following thoracic surgery, with limited relief from traditional analgesic modalities. Each patient was evaluated as a candidate for percutaneous ultrasound-guided intercostal cryoneurolysis (USG-IC), in conjunction with regional anesthesia techniques. Following cryoneurolysis, each patient reported significant pain relief, as was exhibited by a reduction in pain scores, as well as weaning from opioid consumption over the course of weeks to months, ultimately facilitating overall recovery.

Given our experiences using percutaneous cryoneurolysis as an analgesic strategy in oncologic thoracic surgery, it could be beneficial to further explore optimizing patient selection, timing of intervention, as well as standardizing procedural technique. The benefits of cryoneurolysis include a relatively lowrisk profile and the potential for extended analgesia, surpassing that of other modalities all while limiting the need for opioids.

Perioperative analgesic goals aim to reduce postoperative acute pain, opioid requirements, and opioid-related adverse drug events (ORADES), while improving functional recovery and reducing the incidence of chronic pain syndromes. Percutaneous intercostal cryoneurolysis offers a promising opioid-sparing analgesic strategy in oncologic thoracic surgery to facilitate postoperative recovery and reduce post-surgical pain symptoms.

Previous Next

Keywords

Regional anesthesia; Cryoneurolysis; Thoracic surgery; Post-thoracotomy pain; Chronic pain

1. Introduction

Thoracic surgery remains a cornerstone in oncologic management of chest malignancies, yet is often accompanied by a challenging postoperative pain trajectory. Even with minimally invasive surgical techniques and enhanced recovery protocols, post-thoracotomy pain syndrome (PTPS) and chronic pain continue to be prevalent complications. PTPS is defined as pain that recurs or persists along the thoracotomy surgical incision for at least two months after surgery, and often involves neuropathic pain as a prevalent component. Despite reported variability, the incidence of PTPS ranges from 25% to 40%, with some reports indicating up to 60% or more [[1], [2], [3], [4]]. Progression of acute pain symptoms to chronic pain leads some patients to rely on opioids and other analgesics to manage the debilitating impact on their quality of life. Furthermore, in the immediate post-thoracotomy period, inadequate pain relief can lead to compromised pulmonary mechanics, increased risk of atelectasis and pneumonia, and need for prolonged respiratory support.

Regional and neuraxial anesthesia techniques have limitations in providing prolonged analgesia, even when using an indwelling catheter or local anesthetic formulations to extend duration of effect. Thus, opioids in conjunction with other analgesic adjuncts are often necessary to manage persistent postoperative pain. Undesirable opioid side effects, such as respiratory depression, altered mental status, sedation, and ileus, can all contribute to delayed recovery and increased hospital length of stay. Long-term reliance on opioids can prolong adverse drug events, and potentiate the risk of addiction/misuse amidst the existing opioid epidemic.

Cryoneurolysis involves direct application of targeted cold temperatures (−20 to −100 degrees Celsius), resulting in reversible neuronal injury via Wallerian degeneration [5]. With preservation of the endoneurium, the affected nerve regenerates over the course of weeks to months, providing an analgesic window [6]. Cryoneurolysis has been used in palliative care and chronic pain conditions, including postherpetic and occipital neuralgia, intercostal neuralgia, and phantom limb pain [7]. More recently, percutaneous cryoneurolysis has expanded into acute pain management, aiming to achieve extended analgesic effect [8]. This tool is relevant in post-thoracotomy pain due to the prolonged nature of pain symptoms associated with thoracic surgery. Indeed, several studies and reports have identified the advantage of intercostal nerve cryoneurolysis for chest wall analgesia, including in post-mastectomy pain, post-thoracotomy pain, and in the setting of traumatic rib and/or sternal fractures [[8], [9], [10], [11], [12], [13], [14], [15], [16]].

This case series presents clinical scenarios demonstrating the utility of percutaneous ultrasound-guided intercostal cryoneurolysis (USG-IC) as an analgesic rescue for post-thoracotomy patients. In addition, it

provides a rationale for evaluating the potential contribution of this intervention in the multifaceted approach to reducing acute postoperative pain and subsequent progression to chronic pain in this patient population.

2. Methods

At our institution, comprehensive perioperative care of thoracic surgery patients is supported by an Enhanced Recovery After Surgery (ERAS) protocol. This protocol incorporates preoperative medications (celecoxib and gabapentin), intraoperative multimodal intravenous analgesia, surgeon-directed multilevel posterior T4-T8 intercostal nerve blocks with liposomal bupivacaine, and postoperative multimodal management (acetaminophen, ketorolac/celecoxib, gabapentin, methocarbamol) with opioids as needed for rescue. Despite these strategies, a subset of patients continues to have prolonged postoperative pain. In the case descriptions detailed below, our inpatient acute pain team was consulted for consideration of intercostal cryoneurolysis as a rescue intervention.

For each case, informed patient consent was obtained for regional anesthesia and percutaneous cryoneurolysis, in addition to consent for inclusion of relevant non-identifiable clinical information. Institutional IRB submission determined that this case series meets criteria for IRB exemption. Also, CARE case report guidelines were followed for this case series submission.

To proceed with intercostal cryoneurolysis, the patient was initially positioned lateral decubitus or prone (Fig. 1-A). Standard monitors were applied including non-invasive blood pressure monitoring, continuous pulse oximetry, and electrocardiography. Relevant thoracic intercostal levels were identified with ultrasound technique, scanning along the posterior paramedian chest wall starting from the first rib. The target site for each intercostal nerve was identified near the neurovascular bundle, at or just medial to the medial border of the innermost intercostal muscle. Prior to initiating cryoneurolysis, the use of regional anesthesia (erector spinae plane – ESP block or paravertebral block - PVB) and local infiltration with 1% lidocaine at the skin ensured patient comfort during freezing cycles.

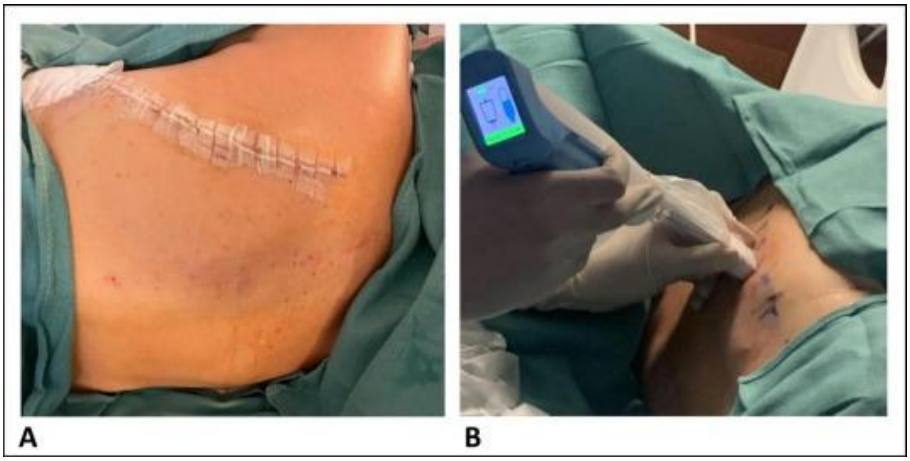

Download: Download high-res image (113KB)
Download: Download full-size image

Fig. 1. Postoperative chest wall incision following open thoracotomy with lateral decubitus patient positioning prior to percutaneous cyroneurolysis along posterior intercostal spaces **(A)** Linear ultrasound placement with in-plane advancement of handheld cryoprobe 20-guage, 90mm needle (Iovera, Pacira BioSciences, USA) **(B).**

Using sterile technique and a high-frequency linear ultrasound probe, a handheld cryoprobe (Iovera, Pacira BioSciences, USA) with a 20-gauge, 90 mm needle was advanced in-plane in a cephalad trajectory into the intercostal space near the neurovascular bundle (Fig. 1-B). Once needle placement was visualized deep to the internal intercostal muscle, the cryoprobe was activated to perform a freezing/cooling cycle lasting approximately 108 s (Fig. 2). Two sequential treatment cycles were performed at each clinically relevant intercostal space, plus one level above and below, accounting for overlap from adjacent sensory dermatomes. Once complete, the patient was monitored for any changes in clinical status. Afterwards, progression in pain symptoms (NRS – Numeric Rating Scale, 0–10) and opioid use were documented, including follow-up visits over the course of three to six months.

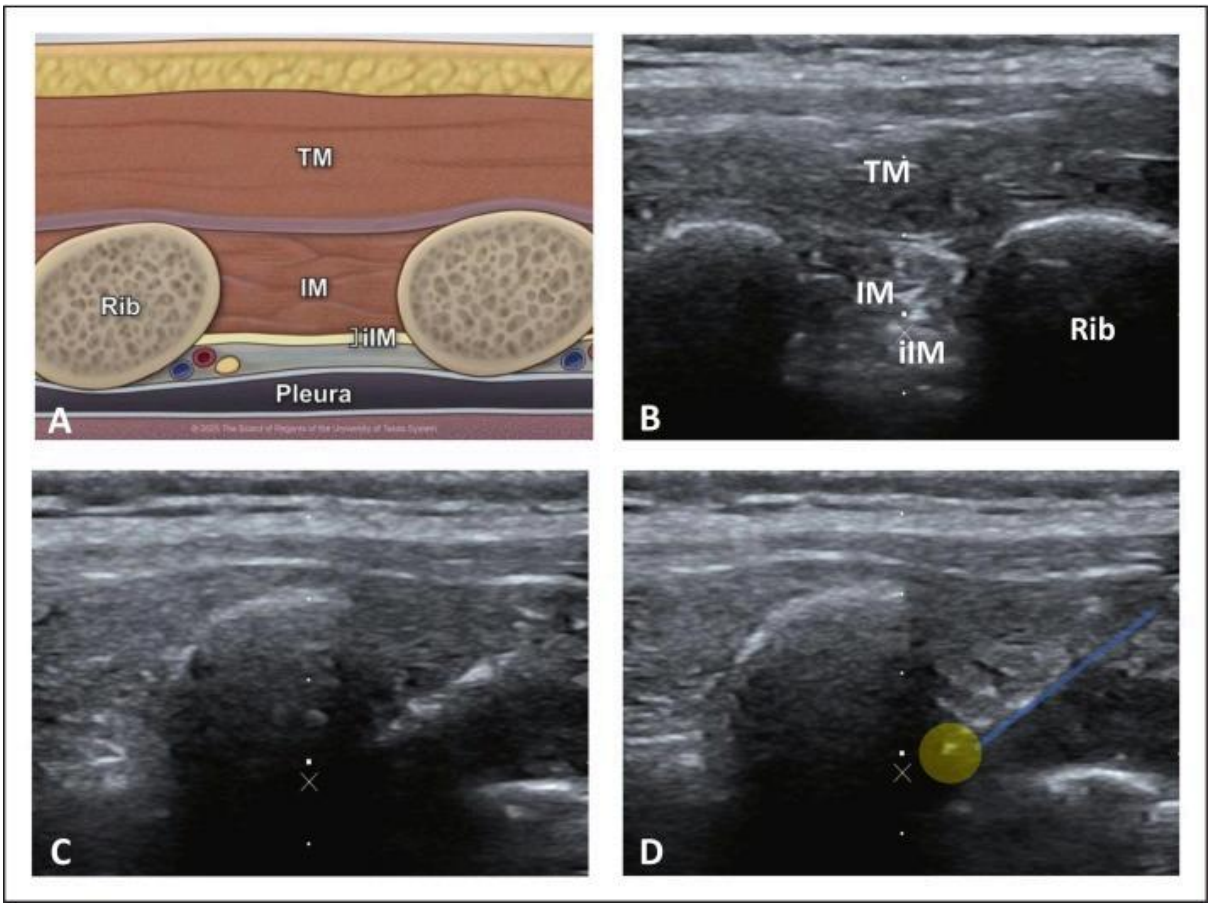

Download: Download high-res image (565KB)

Download: Download full-size image

Fig. 2. Illustrated depiction and corresponding ultrasound images in sagittal orientation of posterior intercostal space. Relevant anatomical structures for identification of intercostal nerve caudal to targeted rib **(A, B)**. Echogenic cryoprobe needle advancement in-plane towards targeted intercostal nerve **(C)**. Highlighted cryoprobe needle (blue) with hypoechoic ice ball formation (yellow) at needle tip **(D)**. TM: Trapezius Muscle, IM: Intercostal Muscle, iIM: Internal Intercostal Membrane, Rib: Posteior thoracic rib. (For interpretation of the references to colour in this figure legend, the reader is referred to the web version of this article.)

3. Case descriptions

3.1. Case 1

A 61-year-old woman with lung adenocarcinoma underwent robotic left upper lobe lobectomy complicated by torsion, thus requiring completion pneumonectomy. In addition to poor oral intake and significant weight loss following her surgery, she experienced persistent debilitating post-surgical pain. She described stabbing incisional and neuropathic pain along the lower chest for over six months following surgery, despite trialing various opioid regimens (methadone, hydromorphone, morphine, hydrocodone).

Initially, a T4 ESP block was performed with 20 ml of 0.5% ropivacaine to provide symptom relief. Once positioned prone, T3-T7 intercostal cryoneurolysis was performed with at least two freezing cycles at each intercostal level (3 cycles were performed at levels T4-T6 following minor needle adjustments). Immediately following the procedure, the patient described complete resolution of her chest wall pain.

After one month, the patient reported minimal residual chest wall pain. Further follow-up was complicated by an episode of acute cholecystitis requiring surgery as well as worsening chronic back pain. At her 5-month (post-cryoneurolysis) clinic visit, the patient reported mostly chronic back pain, but no complaints related to her prior chest wall pain.

3.2. Case 2

A 73-year-old woman with lung adenocarcinoma underwent right thoracotomy for upper lobe lobectomy. The patient was discharged on postoperative day (POD) 7, but a week later returned to clinic with severe incisional pain along her back and chest wall. Despite using acetaminophen, celecoxib, gabapentin, methocarbamol, and oxycodone 5 mg six times daily, which she found sedating, she reported persistent stabbing pain with 9/10 intensity.

At that time, approximately three weeks after her initial surgery, the patient agreed to proceed with intercostal cryoneurolysis. Initially, a T5 ESP block was performed with 35 ml of 0.25% bupivacaine and 10 mg preservative-free (PF) dexamethasone. Subsequently, once positioned prone, right-sided T5-T8 intercostal cryoneurolysis was performed with two treatment cycles at each intercostal level. Following the procedure, she described noticeable improvement in her symptoms, with a reported pain score of 2/10.

At one-month follow-up, the patient stated that her surgical pain remained minimal, requiring only gabapentin and hydrocodone-acetaminophen tablets as needed for breakthrough pain. After three months following cryoneurolysis, she continued to experience significant symptom relief, with no reports of opioid use.

3.3. Case 3

A 66-year-old woman with epithelioid mesothelioma underwent left thoracotomy, pleurectomy/decortication, pericardiectomy, and reconstruction of the diaphragm. She was initially discharged on POD 5, but presented to the emergency room days later with unrelenting chest wall pain. The patient had maximized her analgesic (acetaminophen, gabapentin, ibuprofen, methocarbamol) and opioid options (tramadol, hydromorphone), yet still complained of severe incisional and neuropathic chest wall pain.

Initially, a T4 ESP block was performed with 30 ml of 0.25% bupivacaine and 5 mg PF dexamethasone. Afterwards, in the right lateral decubitus position, T2-T8 ultrasound-guided intercostal cryoneurolysis was performed with two treatment cycles at each intercostal level. No complications were encountered and the patient endorsed significant pain relief immediately afterwards. She only noted mild residual pain along the

anterior edge of her incision near the level of the diaphragm. Due to her marked improvement in symptoms, the patient was discharged home the same day after the procedure.

Three weeks following cryoneurolysis, she continued to report significant pain relief, only requiring acetaminophen for chest wall "tightness". After one month, she described cycles of "pain episodes" along the chest wall, but these symptoms were easily mitigated by acetaminophen and meloxicam. At the three-month follow-up, she mostly endorsed muscle spasms, treated with tizanidine as needed.

3.4. Case 4

A 57-year-old woman with renal clear cell carcinoma complicated by tumor thrombus underwent open radical nephrectomy and level 1 thrombectomy. Subsequent imaging revealed primary lung adenocarcinoma, and thus, approximately two months after her initial nephrectomy, the patient underwent robotic-assisted segmentectomy of the right lower lobe.

The patient had an uneventful postoperative course but was readmitted on POD 10 after several days of persistent abdominal, chest wall, and back pain unrelieved by high-dose opioids (morphine, hydromorphone, fentanyl patch). The acute pain team was consulted and proceeded with a combination of procedural interventions.

Initially, to address the abdominal pain, likely secondary to her prior nephrectomy, anterior quadratus lumborum (QL) and external oblique intercostal (EOI) fascial plane blocks were performed with 0.25% bupivacaine and 1.3% liposomal bupivacaine. For the chest wall pain, an initial T5-T7 PVB was performed (two separate injections) with 20 ml of 0.25% bupivacaine with 10 mg PF dexamethasone, followed by intercostal cryoneurolysis at T5-T9 with two freezing cycles at each level.

Following the combination of procedures, the patient reported complete resolution of her multifaceted pain. She was subsequently cleared for discharge less than 36 h after initially presenting with intractable pain. On follow-up six weeks later, the patient reported minimal postsurgical pain (2/10) and was taking only gabapentin with hydromorphone tablets as needed for breakthrough pain. At two months post-cryoneurolysis, she reported limited to no pain, and was no longer taking any opioids. After 3 months, the patient was no longer taking any form of medication for pain symptoms.

4. Discussion

This case series highlights the efficacy and promising impact of percutaneous ultrasound-guided intercostal cryoneurolysis (USG-IC) in the setting of persistent post-thoracotomy pain. Specifically, we describe our individual experience, the progression of technique and strategies, and future insights for pain management in our oncologic patient population.

In each clinical scenario, our patients presented at variable time points in their postoperative recovery, and each with unique symptoms and severity. However, uniformly, these patients endorsed persistent post-surgical pain, despite comprehensive multimodal analgesic management. Of note, patient 1 exhibited characteristics of PTPS and chronic post-surgical pain at six months following her surgery. This prolonged period of symptoms can transform into a multifactorial pain profile that is challenging to manage, with contributions from central sensitization, hyperalgesia, opioid tolerance, and other aggravating factors.

In the literature, PTPS is often reported to be mild in intensity, but may still have a debilitating impact on quality of life and physical function [3]. Despite variability in reported incidence of PTPS, it has been demonstrated that neuropathic pain tends to be the most prevalent component [1]. Targeted nerve cryoneurolysis has been utilized for treatment of neuropathic pain in the chronic pain setting, and thus, has potentially relevant application to PTPS in addition to acute pain management [7]. However, the mode of cryoneurolysis delivery appears to be significant, as studies evaluating direct cryoneurolysis with exposed nerve targets have demonstrated an increased risk of subsequent neuropathic pain [[17], [18], [19], [20]]. This is theorized to be due to a "double-crush phenomenon" with the combined insult from direct tissue/nerve disruption during surgery and additional nerve cryoneurolysis [21]. In contrast, the use of percutaneous USG-IC has not been correlated with secondary neuropathic pain, further highlighting an important advantage of this technique [8,24,25]. In our patient cohort, there were no reports of neuralgia following cryoneurolysis, in addition to no procedural complications (e.g. tissue damage, hematoma, pneumothorax, hemothorax).

For each of our patients, percutaneous USG-IC provided effective pain relief with evidence of prolonged analgesic benefit. In case 1, despite presenting with chronic postsurgical pain, the patient endorsed notable improvement following USG-IC, which facilitated opioid weaning in the setting of concomitant chronic back and abdominal pain. In the context of multiple sources of pain, we were unable to quantify the full extent of analgesia provided by USG-IC for this particular case. However, for patients 2,3, and 4, USG-IC was performed within three weeks of surgery and each patient experienced significant relief, with an extended analgesic effect that resulted in an opioid-free state within two to three months post-cryoneurolysis. Although we did not measure hospital length of stay as an immediate outcome for our patients due to their variable clinical presentations, this is a measure that could be positively impacted by intercostal cryoneurolysis in the more immediate perioperative phase. During our time evaluating the utility of intercostal cryoneurolysis, we treated an additional two patients that were not described in this case series due to unreliable symptom reporting from one patient and subsequent surgery within the immediate post-cryoneurolysis period for the other patient.

When evaluating our cryoneurolysis procedural technique, several areas of interest were identified. With regards to guiding cryoprobe insertion, several techniques have been described, include landmark-based, nerve stimulation, fluoroscopy, computed tomography, and magnetic resonance imaging [19]. However, an ultrasound-guided percutaneous approach has several advantages, including ease of use and real-time target visualization. For all of our procedures, we also preemptively utilized regional anesthesia (ESP, PVB) to not only facilitate patient comfort during freezing cycles, but to also provide diagnostic reassurance of anticipated symptom relief. Additionally, at least two treatment cycles were delivered with the cryoprobe at each intercostal level, as described in other clinical applications, with the goal to amplify the field of impact [22]. For case 1, we adjusted needle position between paired cycles with the hope of achieving a more complete freezing area. However, due to concern for possible disruption of ice ball formation, the decision was made in subsequent cases to apply two treatment cycles at the same location, without any adjustments after initial needle positioning. These experiences were valuable in impacting the progression of our clinical practice and allowed for more consistent analgesic outcomes.

Overall, there is reassurance in USG-IC providing significant and immediate pain relief, as well as prolonged analgesic benefit in post-thoracotomy patients. These promising clinical outcomes highlight the potential benefit of USG-IC for oncologic thoracic patients, which are at high risk of chronic post-surgical pain and the development of PTPS. Two other case reports have described the positive impact of ultrasound-guided

cryoneurolysis on patients presenting with PTPS [14,21]. In the setting of traumatic rib fractures, several case series have demonstrated the benefit of USG-IC in decreasing pain scores and opioid use, improving incentive spirometry measures, and facilitating weaning from mechanical ventilation [9,15,23]. For post-mastectomy pain, Ilfeld et al. demonstrated the additive benefit of intercostal cryoneurolysis along with regional anesthesia in reducing postoperative opioid consumption and incidence of chronic pain [10].

Benefits of cryoneurolysis include a relatively lowrisk profile, few contraindications, and the potential for an extended duration of analgesic effect, surpassing other modalities of peripheral nerve blockade or neuraxial analgesia. Potential considerations with this intervention include the possibility of incomplete cryoneurolysis leading to neuralgia, extended procedural duration needed for freezing cycles near vulnerable target sites, and localized bruising, bleeding, or skin “frostbite”. Nonetheless, percutaneous USG-IC offers a promising analgesic and opioid-sparing strategy in thoracic surgery with the goal of facilitating recovery, providing extended analgesic benefit, and reducing risk for chronic pain and PTPS.

Moving forward, it would be beneficial to further explore the use of USG-IC for thoracic surgery in order to optimize patient selection, timing of intervention, and standardization of technique. USG-IC could be incorporated as a more definitive and deliberate strategy in perioperative pain management, with a goal of reducing both acute postoperative pain and halting the progression towards chronic pain. Future studies should look to delineate indications, refine procedural protocols, and evaluate impact on long-term outcomes with this intervention.

Funding

No funding was received.

CRediT author statement

All authors have made substantial contributions to all of the following:

1. The conception and design of the manuscript, as well as interpretation of outcomes.
2. Drafting the article or revising it critically for important intellectual content.
3. Final approval of the version to be submitted.

All authors have agreed to be accountable for all aspects of the work to ensure that the questions related to the accuracy or integrity of any part of the work are appropriately investigated and resolved.

Andrzej P. Kwater: Conceptualization, Methodology, Investigation, Writing – Original Draft, Writing – Review & Editing, Visualization.

Keyuri Popat: Conceptualization, Methodology, Investigation, Writing – Review & Editing.

Evan J. Wright: Conceptualization, Investigation, Writing – Review & Editing, Visualization.

David C. Rice: Methodology, Resources, Writing – Review & Editing.

Ravi Rajaram: Methodology, Resources, Writing – Review & Editing.

Gabriel E. Mena: Conceptualization, Methodology, Writing – Original Draft, Writing – Review & Editing, Supervision.

CRediT authorship contribution statement

Andrzej P. Kwater: Writing – review & editing, Writing – original draft, Visualization, Methodology, Investigation, Conceptualization. **Keyuri Popat:** Writing – review & editing, Methodology, Investigation, Conceptualization. **Evan J. Wright:** Writing – review & editing, Visualization, Investigation, Conceptualization. **David C. Rice:** Writing – review & editing, Resources, Methodology. **Ravi Rajaram:** Writing – review & editing, Resources, Methodology. **Gabriel E. Mena:** Writing – review & editing, Writing – original draft, Supervision, Methodology, Conceptualization.

Declaration of competing interest

None.

Recommended articles

Data availability

No data was used for the research described in the article.

References

[1] S. Arends, A.B. Böhmer, M. Poels, M. Schieren, A. Koryllos, F. Wappler, *et al.*
Post-thoracotomy pain syndrome: seldom severe, often neuropathic, treated unspecific, and insufficient
Pain Rep, 5 (2) (2020 Mar 4), Article e810
Crossref ↗ View in Scopus ↗ Google Scholar ↗

[2] V. Guastella, G. Mick, C. Soriano, L. Vallet, G. Escande, C. Dubray, *et al.*
A prospective study of neuropathic pain induced by thoracotomy: incidence, clinical description, and diagnosis
Pain, 152 (1) (2011 Jan), pp. 74-81
View PDF View article Crossref ↗ View in Scopus ↗ Google Scholar ↗

[3] M.A. Kinney, W.M. Hooten, S.D. Cassivi, M.S. Allen, M.A. Passe, A.C. Hanson, *et al.*
Chronic postthoracotomy pain and health-related quality of life
Ann Thorac Surg, 93 (4) (2012 Apr), pp. 1242-1247
View PDF View article View in Scopus ↗ Google Scholar ↗

[4] P. Kar, K.D. Sudheshna, D. Padmaja, A. Pathy, R. Gopinath
Chronic pain following thoracotomy for lung surgeries: it's risk factors, prevalence, and impact on quality of life - a retrospective study
Indian J Anaesth, 63 (5) (2019 May), pp. 368-374
Crossref ↗ View in Scopus ↗ Google Scholar ↗

[5] B.M. Ilfeld, J. Preciado, A.M. Trescot
Novel cryoneurolysis device for the treatment of sensory and motor peripheral nerves
Expert Rev Med Devices, 13 (8) (Aug 2016), pp. 713-725
Crossref ↗ View in Scopus ↗ Google Scholar ↗

[6] J.J. Finneran Iv, B.M. Ilfeld
Percutaneous cryoneurolysis for acute pain management: current status and future prospects
Expert Rev Med Devices, 18 (6) (2021 Jun), pp. 533-543
Crossref ↗ Google Scholar ↗

[7] B.M. Ilfeld, R.A. Gabriel, A.M. Trescot
Ultrasound-guided percutaneous cryoneurolysis for treatment of acute pain: could cryoanalgesia replace continuous peripheral nerve blocks?
Br J Anaesth, 119 (4) (Oct 1 2017), pp. 703-706
Crossref ↗ Google Scholar ↗

[8] B.M. Ilfeld, J.J. Finneran
Cryoneurolysis and percutaneous peripheral nerve stimulation to treat acute pain
Anesthesiology, 133 (5) (2020 Nov 1), pp. 1127-1149
Crossref ↗ View in Scopus ↗ Google Scholar ↗

[9] J.J. Finneran Iv, R.A. Gabriel, M.W. Swisher, *et al.*
Ultrasound-guided percutaneous intercostal nerve cryoneurolysis for analgesia following traumatic rib fracture -a case series
Korean J Anesthesiol, 73 (5) (Oct 2020), pp. 455-459
Crossref ↗ Google Scholar ↗

[10] B.M. Ilfeld, J.J. Finneran, M.W. Swisher, E.T. Said, R.A. Gabriel, J.F. Sztain, *et al.*
Preoperative ultrasound-guided percutaneous Cryoneurolysis for the treatment of pain after mastectomy: a randomized, participant- and observer-masked
Sham-controlled Study Anesthesiology, 137 (5) (2022 Nov 1), pp. 529-542
Crossref ↗ View in Scopus ↗ Google Scholar ↗

[11] A.P. Kwater, S. Sen, J.B. de Haan, M.A. Ge, A.M. Kim, N. Hernandez
Ultrasound-guided percutaneous cryoneurolysis for management of acute sternal fracture pain
Trauma Case Rep, 3 (43) (2023 Jan), Article 100751
View PDF View article View in Scopus ↗ Google Scholar ↗

[12] S.C. Eierle, A.B. Anderson, P.S. Mullinex, B.K. Potter
Utilising intraoperative hand-held cryoneurolysis for enhanced post-thoracotomy pain control
BMJ Case Rep, 18 (4) (2025 Apr 28), Article e263745
Crossref ↗ View in Scopus ↗ Google Scholar ↗

[13] R.A. Gabriel, J.J. Finneran, M.W. Swisher, E.T. Said, J.F. Sztain, B. Khatibi, *et al.*

Ultrasound-guided percutaneous intercostal cryoanalgesia for multiple weeks of analgesia following mastectomy: a case series
Korean J Anesthesiol, 73 (2) (2020 Apr), pp. 163-168
Crossref ↗ View in Scopus ↗ Google Scholar ↗

[14] M.G. Byas-Smith, A. Gulati
Ultrasound-guided intercostal nerve cryoablation
Anesth Analg, 103 (4) (2006 Oct), pp. 1033-1035
Crossref ↗ View in Scopus ↗ Google Scholar ↗

[15] J.D. Forrester, S. Wang, A.A. Myers, M. Earley, S. Guthrie-Baker, A. Abreo, *et al.*
Ultrasound-guided percutaneous cryoneurolysis of intercostal nerves in traumatic rib fractures
Injury, 56 (5) (2025 May), Article 112321
View PDF View article View in Scopus ↗ Google Scholar ↗

[16] R.A. Gabriel, R. Kestenholz, I. Filipovski
Repeated ultrasound-guided percutaneous intercostal Cryoneurolysis for the Management of Chronic Postmastectomy Pain Syndrome: a case report
A A Pract, 18 (3) (2024 Feb 27), Article e01764
Crossref ↗ Google Scholar ↗

[17] H. Ju, Y. Feng, B.X. Yang, J. Wang
Comparison of epidural analgesia and intercostal nerve cryoanalgesia for post-thoracotomy pain control
Eur J Pain, 12 (3) (2008 Apr), pp. 378-384
View PDF View article Crossref ↗ View in Scopus ↗ Google Scholar ↗

[18] S.T. Mustola, J. Lempinen, E. Saimanen, P. Vilkko
Efficacy of thoracic epidural analgesia with or without intercostal nerve cryoanalgesia for postthoracotomy pain
Ann Thorac Surg, 91 (3) (2011 Mar), pp. 869-873
View PDF View article View in Scopus ↗ Google Scholar ↗

[19] R. Park, M. Coomber, I. Gilron, H. Shanthanna
Cryoanalgesia for postsurgical pain relief in adults: a systematic review and meta-analysis
Ann Med Surg (Lond), 5 (69) (2021 Aug), Article 102689
View PDF View article View in Scopus ↗ Google Scholar ↗

[20] P.I. Cha, J.G. Min, A. Patil, J. Choi, N.N. Kothary, J.D. Forrester
Efficacy of intercostal cryoneurolysis as an analgesic adjunct for chest wall pain after surgery or trauma: systematic review
Trauma Surg Acute Care Open, 6 (1) (2021 May 18), Article e000690
Crossref ↗ View in Scopus ↗ Google Scholar ↗

[21] J. Perese, J. Oswald, R.A. Gabriel

Ultrasound-guided percutaneous Cryoneurolysis for post-thoracotomy pain syndrome: a case report
Cureus, 14 (12) (2022 Dec 23), Article e32888
Google Scholar ↗

[22] E.T. Said, B.P. Marsh-Armstrong, S.J. Fischer, P.J. Suresh, M.W. Swisher, A.M. Trescot, *et al.*
Relative effects of various factors on ice ball formation and ablation zone size during ultrasound-guided percutaneous Cryoneurolysis: a laboratory investigation to inform clinical practice and future research
Pain Ther, 12 (3) (2023 Jun), pp. 771-783
Crossref ↗ View in Scopus ↗ Google Scholar ↗

[23] C.I. Villalta, R.K. Mian, H.M. Grossman Verner, D. Farsakh, T.C. Browne, Z.S. Goldstein, *et al.*
Bedside percutaneous cryoneurolysis technique for management of acute rib fracture pain in adult trauma patients
Trauma Surg Acute Care Open, 9 (1) (2024 Aug 22), Article e001521
Crossref ↗ View in Scopus ↗ Google Scholar ↗

[24] S.H. Wilson, N. Hernandez, E. Said
Regional Anesthesia with Cryoneurolysis: An ancient technique with new possibilities for acute pain
Springer, Current Anesthesiology Reports (2024 Jan 10)
Google Scholar ↗

[25] B.M. Ilfeld, R. Wagner
Cryoneurolysis: interest and caution: comment
Anesthesiology, 139 (1) (2023 Jul 1), pp. 112-113
Crossref ↗ View in Scopus ↗ Google Scholar ↗

Cited by (0)

© 2025 The Authors. Published by Elsevier Inc.

ELSEVIER

All content on this site: Copyright © 2026 Elsevier B.V., its licensors, and contributors. All rights are reserved, including those for text and data mining, AI training, and similar technologies. For all open access content, the relevant licensing terms apply.
RELX™